

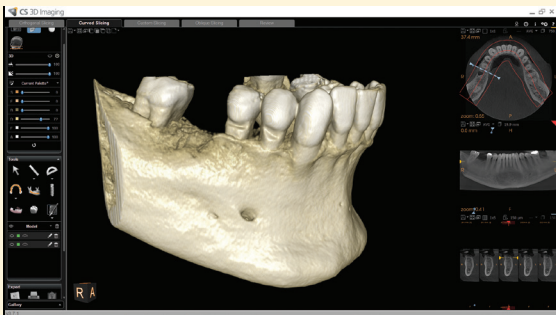
Prosthetic-Driven Implant Planning

Prosthetic-Driven Implant Planning and Its Effect on Implant Placement

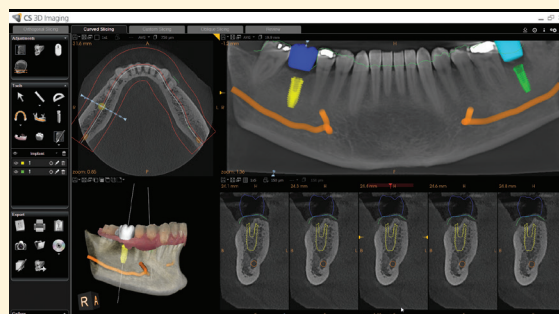
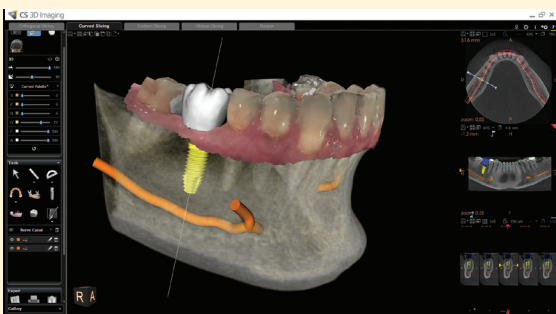
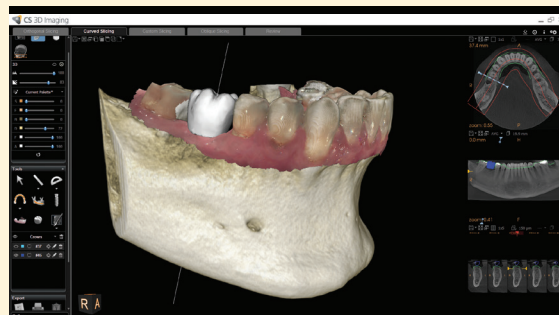
Dr. Marks, Advanced Smile Solutions

Case Overview

A 52-year-old male presented to the office with multiple broken teeth. He had not been seen by a dentist for 8-9 years. The teeth were extracted, a full-arch scan was performed with the CS 8100 3D, and a digital impression was created with the CS 3600. The data sets from both scans were merged using CS 3D Imaging software to begin restoration planning. The software allowed the placement of a virtual crown in the digital model over the implant area. The software then provided a recommendation on the placement of the implant relative to the location of the virtual crown. This ensures that the implant is perfectly aligned and is compatible with the ideal position of the final restoration.



CBCT showing the bone volume after extraction



Implant planning showing the virtual implant position, the virtual crown and the mandibular nerve

CLINICAL CASE STUDY

This approach to implant planning enables clinicians to envision the final result virtually, and, in this example, resulted in a shift in the angulation of the implant. When the implant software revealed the ideal location of the virtual crown, as well as sufficient bone in the surgical area, the team altered the direction of the implant into a position that was more favorable to the final restoration.

The prosthetic-driven implant approach also reduced the number of appointments—and associated costs—that would have been required in the traditional implant workflow. Thanks to digital imaging, implant planning can be done in front of a computer without adding chair time and the involvement of the lab. For patients on a strict schedule, this reduction in treatment time is invaluable.

Protocol Comparison for Implants Using Surgical Guide and Immediate Loading						
	Visit 1	Visit 2	Visit 3	Visit 4	Visit 5	Visit 6
Traditional	Take multiple impressions; Scan with CBCT	Get bite registration	Confirm functionality and aesthetics with wax model	Perform a dual scan protocol with CBCT	Place implant and take impression with implant in place**	Insert prosthesis
Prosthetic-driven implant planning method	Create HD 3D digital impression; Scan with CBCT; Plan implant*	Place implant and create new HD 3D digital impression with implant in place**	Insert prosthesis	–	–	–

* Complex cases may require an additional appointment for case presentation to the patient

** Depending on the loading protocol, impressions may require an additional appointment

“My training taught me to live by the standard of never beginning a procedure until I could envision the final result. The prosthetic-driven approach to implant placement brings the final result, in a virtual sense, to the forefront of your planning. By starting at the end and working backward, you eliminate all guesswork from the process.”

In the past, implants were placed wherever there was enough available bone, and custom abutments would compensate for misguided angles. The crown was then typically cemented on top. The problem with this approach is that cemented crowns are not retrievable if, for example, the abutment screw loosens. The clinician has to either destroy the crown or drill through it to access the screw hole.

Using prosthetic-driven implant planning, clinicians can place more screw-retained crowns. The implant planning software enables them to determine if angulation of the implant and abutment is necessary and what it should be. The software also identifies where to retrieve the screw. This approach results in a more esthetic and functional crown—that is also retrievable.

Patient Communication and Case Acceptance

Prosthetic-driven planning lends itself to improved patient education. When this patient saw all of his images and the step-by-step approach, the whole process became more tangible to him. He felt comfortable and confident enough to accept the treatment plan and begin the process.

“Prosthetic-driven implant planning helps us achieve predictability in implant placement,” said Dr. Marks. “With images from the CS 8100 3D and the CS 3600, we know the exact size of the implant and the angulation well before we begin the surgery. We can envision potential complications and prepare accordingly. We say, ‘If A, B or C happens, we’ve got X, Y or Z to address it.’”

Lawrence H. Marks, D.M.D.



Advanced Smile Solutions

- Bachelor of Arts – Tulane University
- Doctor of Dental Medicine – Tufts University School of Dental Medicine
- Certificate in Prosthodontics – Tufts University School of Dental Medicine

Professional Appointments:

- Former Head of Prosthodontics, General Practice Residency – University of Miami Jacksonville Memorial Hospital
- Former Clinical Instructor, Department of Restorative Dentistry – Tufts University School of Dental Medicine

To learn more about Carestream Dental, go to carestreamdental.com.